

Case Report

Unusual Presentation Of Uterine Rupture In A Low Resource Setting: A Case Report And Review Of Literature

*Omagbe O¹, Ozakpo O¹, Odunvbun WO^{1,2}, Ogwu RO³

¹Department of Obstetrics and Gynaecology, Delta State University Teaching Hospital, Oghara, Delta State Nigeria

²Department of Obstetrics and Gynaecology, Faculty of clinical sciences, Delta State University, Abraka, Delta State Nigeria

³Department of Obstetrics and Gynaecology, Federal Medical Centre, Asaba, Delta State Nigeria

Article History

Submitted: 20/04/2026, Accepted: 28/04/2026, Published: 15/05/2026

*Correspondence: Dr Orighomisan Omagbe

Email: misandone@gmail.com,

Phone: +2347036298591, ORCID ID: 0009-0006-5669-5675

ABSTRACT

Uterine rupture is an obstetric emergency that can be fatal. It is of public health importance in developing countries because of the high risk of maternal and fetal mortality associated with it. The incidence of uterine rupture is 1.3% in Africa. The rates of uterine rupture in Nigeria, range from 1 in 81 to 1 in 426 births. Despite it been a rare obstetric complication, the mortality rate is about 5%, and the fetal death rate exceeds 65%. A previous uterine scar is the most common risk factor for uterine rupture, especially following a previous cesarean delivery. Although it is uncommon, uterine rupture can sometimes occur without any noticeable symptom. Silent uterine rupture can be very difficult to identify, hence early clinical diagnosis and prompt surgical intervention is paramount to maternal fetal survival. This was a case of Mrs H E, a booked 29 year old G4P3+0(3A), with 1 previous cesarean section in 2023, registered her antenatal care in a primary health care centre. She presented for expert care in anticipation of delivery. At presentation, there were no classical symptoms of uterine rupture and her haemodynamic status was good. However, the fetal parts were easily palpable per abdomen with absent fetal tone. Emergency ultrasound (USG) scan done showed a 3kg foetus with its placenta in the amniotic sac outside the uterine cavity which was empty, with the conclusion of abdominal ectopic gestation. A silent uterine rupture was confirmed intraoperatively. She had laparotomy with uterine repair only and her post-op condition was satisfactory. It is extremely rare for the uterus to rupture silently before, more so with an intact amniotic sac outside the uterine cavity. Making this diagnosis requires a strong index of suspicion and accurate imaging throughout pregnancy.

Keywords: Cesarean section, Laparotomy, Uterine rupture

INTRODUCTION

Uterine rupture is defined as the complete disruption of all uterine layers during pregnancy, labour, or the immediate postpartum period^{1,2,3}. Complete uterine rupture, which involves the endometrium, myometrium, and serosa, is associated with high perinatal morbidity and mortality and may occur with or without expulsion of the fetus into the peritoneal cavity^{1,2,4}. In contrast, partial uterine rupture, which spares either the serosa or membranes, is more common, usually non-catastrophic, and often detected incidentally as uterine dehiscence during elective or emergency pre-labour caesarean section^{1,4}.

Although rare, uterine rupture remains a catastrophic obstetric emergency with serious maternal and fetal consequences^{1,5,6}. Its occurrence is significantly higher in

low-resource settings than in developed countries^{1,2,3,7}. The global incidence is estimated at 0.07%, compared with approximately 1.3% in Africa⁷. Much lower rates have been reported in high-income countries, including 0.007% in the Netherlands, 1 in 16,849 births in the United States, and 0.2 per 1,000 births in the United Kingdom¹. In Nigeria, reported incidence rates range from 1 in 81 to 1 in 426 deliveries, comparable to those in other African countries such as Ghana, Ethiopia, Uganda, and Sudan^{8,9}. Despite advances in obstetric care, uterine rupture is associated with a maternal mortality rate of about 5%, while fetal mortality exceeds 65%⁷.

The most common predisposing factor for uterine rupture is a previous uterine scar, particularly following caesarean birth^{3,10}. Consequently, spontaneous rupture of an unscarred uterus is rare.¹¹ However, uterine rupture may

Article Access



Website: www.wjmb.org

doi: 10.5281/zenodo.20530166

How to cite this article

Omagbe O, Ozakpo O, Odunvbun WO, Ogwu RO. Unusual Presentation Of Uterine Rupture In A Low Resource Setting: A Case Report And Review Of Literature, *West J Med & Biomed Sci.* 2026;7(2):240-244. DOI:10.5281/zenodo.20530166

occasionally be asymptomatic and discovered incidentally during ultrasound examination or surgery, making diagnosis challenging at presentation.^{6,12} Classical signs such as vaginal bleeding, abdominal pain, hemorrhage, or hypovolemic shock may be absent, and reports of such silent ruptures are uncommon.^{6,11,13}

Management requires prompt resuscitation and stabilization, followed by surgical intervention. Options include uterine repair alone, repair with bilateral tubal ligation, or subtotal or total hysterectomy, depending on the site and extent of rupture, haemodynamic status, fertility desires, and surgical expertise.^{13,14}

We present the case of a 29-year-old multiparous woman at 36 weeks and 5 days gestation who presented without classical symptoms of uterine rupture. Clinical examination revealed a soft, non-tender abdomen, easily palpable fetal parts, and absent fetal heart tones. Bedside ultrasound suggested an abdominal ectopic pregnancy with intrauterine fetal demise, as no uterine wall defect was visualized, creating a diagnostic dilemma.

Silent uterine rupture is rare and difficult to diagnose because of their unclear and sometimes non-specific symptoms overlapping with other cases such as ectopic pregnancy. Hence the diagnosis may be challenging and may be made only intraoperatively unless confirmed on ultrasonography before surgery.

CASE SUMMARY

A 29-year-old G4P3+0 (with 3 living children) woman with one previous caesarean section presented at 36 weeks and 5 days gestation following referral from a primary health care centre. She got married to her new partner a year ago and this is her first pregnancy for the new partner.

She had no classical symptoms of uterine rupture and reported absence of fetal movements for about 12 hours. There was a history of repeated abdominal massage associated with mild, intermittent abdominal pain. There was no vaginal bleeding, abdominal distension, syncope, or features of hypovolemic shock.

On examination, she was haemodynamically stable. The abdomen was soft and non-tender with a healed Pfannenstiel scar; fetal parts were easily palpable in breech presentation, and fetal heart tones were absent. Vaginal examination revealed a closed, posterior cervix with no vaginal bleeding. A provisional diagnosis of intrauterine fetal death in a woman with a previous caesarean section and suspected uterine rupture was made.

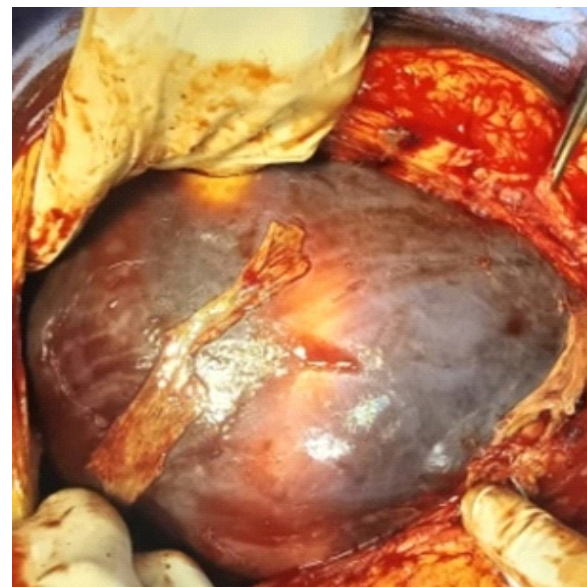
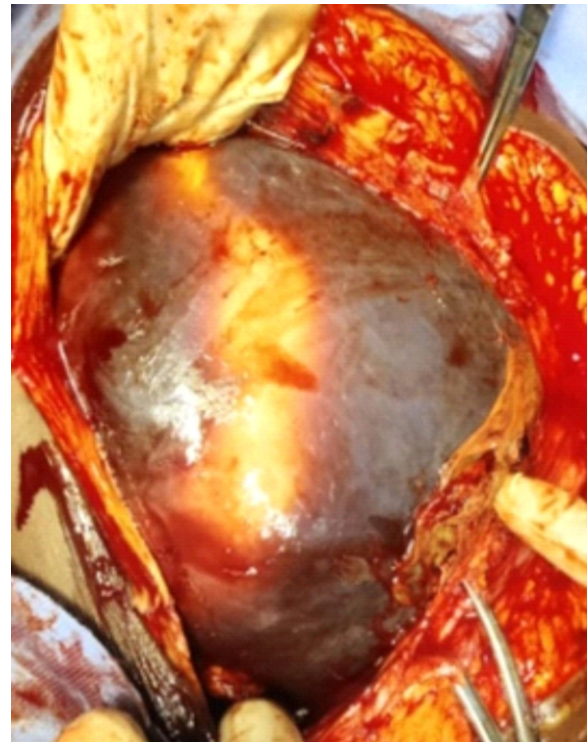
Laboratory evaluation showed a packed cell volume of 32% (Hb 9.8 g/dL). Urgent ultrasound scan done revealed a singleton breech presenting extra-uterine foetus without demonstrable fetal cardiac activity with amniotic sac extending from the left hypochondrium to the left lumbar region. There was mild free intraperitoneal fluid collection. There was a bulky uterus measuring about 16.23cm x 10.56cm x 11.04cm, the endometrial cavity was empty and the internal cervical os was closed. The impression was an abdominal ectopic pregnancy with fetal demise.

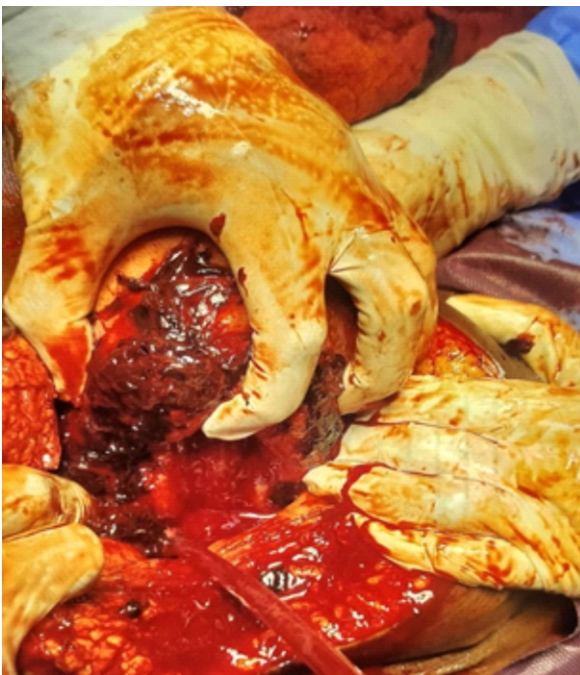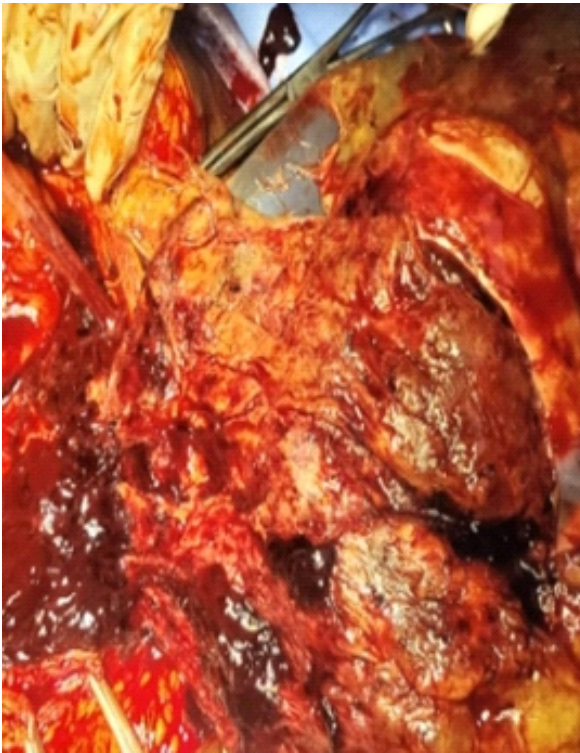
Following counselling and multidisciplinary review, she underwent exploratory laparotomy. Intraoperative findings included a fresh stillborn fetus and placenta completely enclosed within an intact amniotic sac in the abdominal cavity, approximately 600 mL of hemoperitoneum, and a 10 cm transverse lower uterine rupture along the previous

caesarean scar filled with old clots. The uterus was approximately 16-week size, with normal adnexa. The rupture edges were refreshed and repaired in two layers using Vicryl 2 sutures. Estimated blood loss was 500 mL, and she received two units of blood intraoperatively.

Bilateral tubal ligation was not done for her as she showed a strong aversion for it, citing that this is her first pregnancy for the current partner.

Her immediate postoperative course was satisfactory. She received intravenous antibiotics for 72 hours, later converted to oral therapy. She developed postoperative hypertension on day four, which was managed medically. She was discharged in stable condition on postoperative day ten after counselling and consent for publication.





Intra-abdominal findings of emergency exploratory laparotomy

CASE DISCUSSION

The majority of uterine rupture cases occur in the context of a scarred uterus, and they can result in considerable maternal and neonatal morbidity^{5,11}. The sharp rise in the number of prior cesarean deliveries in recent years is the primary cause of uterine rupture^{15,16}, and more recently, the

growing desire to give a wider variety of patients the option of a labor trial following a cesarean section.^{6,17} Uterine rupture is more common and has more severe repercussions in underdeveloped countries than in industrialized because of poverty, illiteracy, shortage of skilled personnel, and inadequate facilities^{9,16}.

Although rare, silent uterine rupture can occur with no obvious symptoms. Silent uterine rupture can be spontaneous or caused by abdominal trauma, connective tissue disorders, rupture of a previous uterine scar, uterine malformation, or placental abruption, among others.¹⁸ Seldom have such silent ruptures been discovered by mistake.^{6,17} Since the clinical signs of uterine rupture may not be present, silent uterine rupture can be extremely challenging to detect especially where there are no ultrasound evaluation in early pregnancy to rule out abdominal pregnancy as was seen in this case.⁶ A review of the literature revealed a case of a 23-year-old pregnant female in her third trimester (32 weeks), with two prior cesarean deliveries, who had a routine ultrasound scan done in her antenatal care visit that revealed a complete uterine rupture with extrusion of the foetus with no cardiac activity in the intact amniotic sac to the abdominal cavity¹⁸. Our patient has had a previous cesarean section and subsequently had several sessions of abdominal massage, most of which was accompanied by abdominal pain, though mild. It is impossible to pinpoint the precise moment of the rupture because the patient's intermittent pain following each session of abdominal massage was disregarded and no serious symptoms were present. Although the fetal death had taken place at least a week prior to our scan, it is possible that it may have survived for a few weeks outside the uterus in the absence of a verified chronology. With contraction of the uterus and the tamponade effect of the foetus and amniotic sac, the uterine rupture can remain silent.¹⁸ Ultrasound(USG) examination may miss the diagnosis if the contracted uterus is misinterpreted as placenta previa, especially in the presence of vaginal bleeding¹⁸. This was not the case of this patient despite the USG missing the diagnosis. The presence of an empty uterus and the gestational sac above the uterus are the usual ultrasound signs of complete uterine rupture as was seen in this patient⁵.

There are currently extremely few documented instances of quiet uterine rupture accompanied by the delivery of a healthy fetus^{12,19}. This just shows that this unusual and catastrophic condition can still have a favourable outcome sometimes.

It can be extremely hard to anticipate pregnant women who are likely to rupture their uteruses during pregnancy.⁶ Several studies have attempted to create prediction models for uterine rupture, such as sonographic evaluation of uterine scar, but none of them have shown themselves to be trustworthy, particularly after prior traditional cesarean procedures⁷. For clinical usage, they lacked the necessary sensitivity and specificity⁶. Although more research is required to evaluate its practical application, the risk of uterine rupture after cesarean section was directly correlated with the thickness of the lower uterine segment¹⁹. The time required to establish the diagnosis limits the utility of diagnostic imaging techniques like CT

and MRI.

Early surgical intervention is the mainstays of treatment for uterine rupture^{8,13,14,20}. The range of management options includes subtotal abdominal hysterectomy, total abdominal hysterectomy, and repair of the ruptured uterus with or without tubal sterilization, with recoil to long-acting reversible contraception.²¹ These surgical techniques are based on the extent of the uterine rupture, the level of hemorrhage, the overall health of the mother, and the desire for fertility^{8,20}. It is speculated that surgical intervention within 10–37 minutes will reduce the fetus's chance of permanent perinatal injury, especially from intra-abdominal oxidative stress due to reactive species.²² However, delivery within this time frame does not necessarily ensure that the fetus will not have severe hypoxia, or that there won't be any major neonatal consequence later on^{20,23}. Hemorrhage, blood transfusions and its complications, and hysterectomy are severe maternal consequences that can result from uterine rupture. Maternal and perinatal morbidity and mortality are the most fatal outcome of uterine rupture.^{6,7}

CONCLUSION

It is impossible to overstate the importance of antenatal care services and routine ultrasound use in contemporary obstetrics practice because high-risk patients may be monitored not only to assess the general health of the fetus but also to measure scar thickness, and localize the pregnancy to reduce the dilemma of mis-diagnosis.

RECOMMENDATIONS

Uterine rupture is of public health importance especially in low resource setting like ours. Reducing poverty, illiteracy, the lack of qualified personnel, inadequate medical facilities, and declining health-care budget can significantly reduce this avoidable disastrous condition.

DECLARATION OF CONFLICT OF INTEREST

The authors report no conflict of interest or financial support.

REFERENCES

1. Figueiró-Filho EA, Gomez JM, Farine D. Risk Factors Associated with Uterine Rupture and Dehiscence: A Cross-Sectional Canadian Study. *Rev Bras Ginecol e Obstet.* 2021;43(11):8205.
2. Pontis A, Prasciolu C, Litta P, Angioni S. Uterine rupture in pregnancy: Two case reports and review of literature. *Clin Exp Obstet Gynecol.* 2016;43(2):3059.
3. Flis W, Socha MW, Wartęga M, Cudnik R. Unexpected Uterine Rupture A Case Report, Review of the Literature and Clinical Suggestions. *J Clin Med.* 2023;12(10).
4. Al-Zirqi I, Vangen S. Pre labour uterine rupture: characteristics and outcomes. *BJOG An Int J Obstet Gynaecol.* 2020;127(13):163744.
5. Abdulmane MM, Sheikhal OM, Alhowaidi RM, Qazi A, Ghazi K. Diagnosis and Management of Uterine Rupture in the Third Trimester of Pregnancy: A Case Series and Literature Review. *Cureus.* 2023;15(6):16.
6. Woo JY, Tate L, Roth S, Eke AC. Silent Spontaneous Uterine Rupture at 36 Weeks of Gestation. *Case Rep Obstet Gynecol.* 2015;2015:13.
7. Astatikie G, Limenih MA, Kebede M. Maternal and fetal outcomes of uterine rupture and factors associated with maternal death secondary to uterine rupture. *BMC Pregnancy Childbirth.* 2017;17(1):19.
8. Eze JN, Anozie OB, Lawani OL, Ndukwe EO, Agwu UM, Obuna JA. Evaluation of obstetricians surgical decision making in the management of uterine rupture. 2017;411.
9. Adegbola O, Odeseye A. Uterine rupture at Lagos University Teaching Hospital. *J Clin Sci.* 2017;14(1):13.
10. Rottenstreich M, Rotem R, Hirsch A, Farkash R, Rottenstreich A, Samueloff A, et al. Delayed diagnosis of intrapartum uterine rupture maternal and neonatal consequences. *J Matern Neonatal Med [Internet].* 2021;34(5):70813. Available from: <https://doi.org/10.1080/14767058.2019.1613366>.
11. Ekine A, Udoye P, West O. Determinants and Factors influencing the prevalence of uterine rupture in a tertiary rural hospital in the Niger Delta: A 5 years retrospective study in NDUTH, Okolobiri. *Pharma Innov J TPI.* 2015;4(42):97101.
12. Woo JY, Tate L, Roth S, Eke AC, Presentation C. Case Report Silent Spontaneous Uterine Rupture at 36 Weeks of Gestation. 2015;2015:35.
13. Ukah CE, Okhionkpmwonyi O, Okoacha I, Okonta PI. A 5-year review of hysterectomy at the Delta State University Teaching Hospital, Oghara, south-south Nigeria. *Ibom Med J.* 2023;16(3):26872.
14. Okhionkpmwonyi O, Okonta PI. Total abdominal hysterectomy at the Central Hospital, Warri: a five year review. *Borno Med Journal.* 2015;12(1):23-29.
15. Alemu AA, Bitew MS, Gelaw KA, Zeleke LB, Kassa GM. Prevalence and determinants of uterine rupture in Ethiopia: a systematic review and meta-analysis. *Sci Rep [Internet].* 2020;10(1):111. Available from: <https://doi.org/10.1038/s41598-020-74477-z>

16. Motomura K, Ganchimeg T, Nagata C, Ota E, Vogel JP, Betran AP, et al. Incidence and outcomes of uterine rupture among women with prior caesarean section: WHO Multicountry Survey on Maternal and Newborn Health. *Sci Rep*. 2017;7(March):19.
17. Chen L, Li H, Peng J, Li M, Wang Y, Zhao K, et al. Silent uterine rupture in the term pregnancy: Three case reports. *Med (United States)*. 2024;103(10):E37071.
18. Rajoria A, Mittal M, Aggarwal G. A Rare Case of Sonographically Detected Silent Rupture of a Gravid Uterus With Expulsion of a Complete Fetus and an Intact Amniotic Sac. 2025;17(8):15.
19. Langhe R, Shah UF, Alfathil A, Gannon M. Silent uterine rupture in scarred uterus. *BMJ Case Rep*. 2017;2017:20168.
20. Tinelli A, Kosmas IP, Tony J, Howard C, Malvasi A, Cohen SB, et al. Uterine rupture during pregnancy : The URIDA (uterine rupture international data acquisition) study. 2021;(April):19.
21. Omagbe O, Okhionkpwonyi O, Akhator AE. Uptake of Long-acting Reversible Contraception at the Delta State University Teaching Hospital, Oghara, Nigeria: A Three Year Review. *Afr J Health and Social Sci*. 2025;2(1):53-56
22. Okhionkpwonyi O, Okonta PI, Okoacha I, Idogun S. Nitic oxide in infertile female in the niger-delta region of Nigeria. *Niger J Clin Pract*. 2021;24(7):1022-1027.
23. Sayed Ahmed WA, Habash YH, Hamdy MA, Ghoneim HM. Rupture of the pregnant uterus - a 20-year review. *J Matern Fetal Neonatal Med*. 2017 Jun;30(12):1488-1493. doi: 10.1080/14767058.2016.1219997. Epub 2016 Aug 23. PMID: 27487473.